



Claw length recommendations for dairy cow foot trimming

S. C. Archer, R. Newsome, H. Dibble, C. J. Sturrock, M. G. G. Chagunda, C. S. Mason, J. N. Huxley

The aim was to describe variation in length of the dorsal hoof wall in contact with the dermis for cows on a single farm, and hence, derive minimum appropriate claw lengths for routine foot trimming. The hind feet of 68 Holstein-Friesian dairy cows were collected post mortem, and the internal structures were visualised using x-ray μ CT. The internal distance from the proximal limit of the wall horn to the distal tip of the dermis was measured from cross-sectional sagittal images. A constant was added to allow for a minimum sole thickness of 5 mm and an average wall thickness of 8 mm. Data were evaluated using descriptive statistics and two-level linear regression models with claw nested within cow. Based on 219 claws, the recommended dorsal wall length from the proximal limit of hoof horn was up to 90 mm for 96 per cent of claws, and the median value was 83 mm. Dorsal wall length increased by 1 mm per year of age, yet 85 per cent of the null model variance remained unexplained. Overtrimming can have severe consequences; the authors propose that the *minimum* recommended claw length stated in training materials for all Holstein-Friesian cows should be increased to 90 mm.

Introduction

The productivity and welfare of dairy cattle is commonly impeded by lameness (Archer and others 2010a, Huxley 2013). One component of lameness management is therapeutic and prophylactic foot trimming (Bicalho and Oikonomou 2013). The first step of the widely used 'Dutch Method' of cattle foot trimming is to cut the dorsal wall of the claw to 75 mm, derived from the recommendations of Toussaint-Raven (1985) using average values deemed safe for Friesian cows 30 years ago. Cutting the wall too short can lead to overtrimming, which can have severe consequences for the cow (Tsuka and others 2014).

Little peer-reviewed evidence has been published in this area. A review incorporating the grey literature (eg, text books and

other non-peer reviewed literature) identified three areas of inconsistency: (1) the appropriate length to cut the dorsal wall, (2) the landmark of the proximal limit of the dorsal wall and (3) whether to trim the toe to a point or to leave a step; the second two points must be addressed before the first can be answered. Eleven sources related to claw dimensions; of which, two were peer reviewed (Manske and others 2002, Tsuka and others 2014), and the most commonly recommended dorsal wall length was 75–80 mm (eg, Blowey 2004), with a range of 60 (Greenough 2007) to 85 mm (Blowey 2008). Landmarks for the proximal dorsal wall limit were either not defined (eg, Toussaint-Raven 1985) or defined inconsistently; examples included the 'proximal end of claw capsule' (Manske and others 2002), the 'distal edge of the periople' (Tsuka and others 2014) or imprecise terms such as coronary band or coronet (eg, Nuss and Paulus 2006, Blowey 2008). Recommended shape of the toe differed between sources, and different trimming techniques would require adaptation of dorsal wall length to achieve adequate sole thickness. Recommended toe angle varied from 45° to 52°.

Mulling and Budras (2003) reviewed the anatomy of the claw. The coronary band produces wall horn deep to the periople, which consists of the subcutis, dermis and epidermis (perioplic horn). Perioplic horn borders the common integument and overlies the proximal limit of wall horn (Fig 1). The two horn segments appear homogenous before the perioplic horn flakes distally to leave the wall horn as the most superficial layer. The junction between the hoof horn and the common integument appears to be the most consistently definable anatomical structure, and has been used previously as the proximal limit for measuring the dorsal wall during foot trimming (Manske and others 2002).

External measurements applied to the hoof to facilitate trimming are proxies for internal dermis dimensions that cannot be assessed in the live animal without imaging equipment and expertise. Underestimation of the dermis dimensions internal to

Veterinary Record (2015)

doi: 10.1136/vr.103197

S. C. Archer, BVMS, MSc, CertCHP, PhD, MRCVS,

R. Newsome, BVMedSci,

H. Dibble, BVMedSci,

J. N. Huxley, BVetMed, DCHP,

DipECBHM, PhD, MRCVS, School of Veterinary Medicine and Science, University of Nottingham, Sutton Bonington Campus, Sutton Bonington, Loughborough, Leicestershire LE12 5RD, UK

C. J. Sturrock, BSc (Hons), PhD, School of Biosciences, University of Nottingham, Sutton Bonington Campus, Sutton Bonington, Loughborough, Leicestershire LE12 5RD, UK

M. G. G. Chagunda, PhD, MSc, BSc, R.Anim.Sci,

Future Farming Systems, Scotland's Rural College (SRUC), Kings Buildings, West Mains Road, Edinburgh, EH9 3JG, UK

C. S. Mason, BVM&S, BSc, CertCHP, MRCVS,

SAC Consulting Veterinary Services, Scotland's Rural College (SRUC), Kings Buildings, West Mains Road, Edinburgh EH9 3JG, UK

E-mail for correspondence: simon.archer@nottingham.ac.uk

S. C. Archer and R. Newsome are joint first authors of the paper.

Provenance: not commissioned; externally peer reviewed

Accepted June 26, 2015

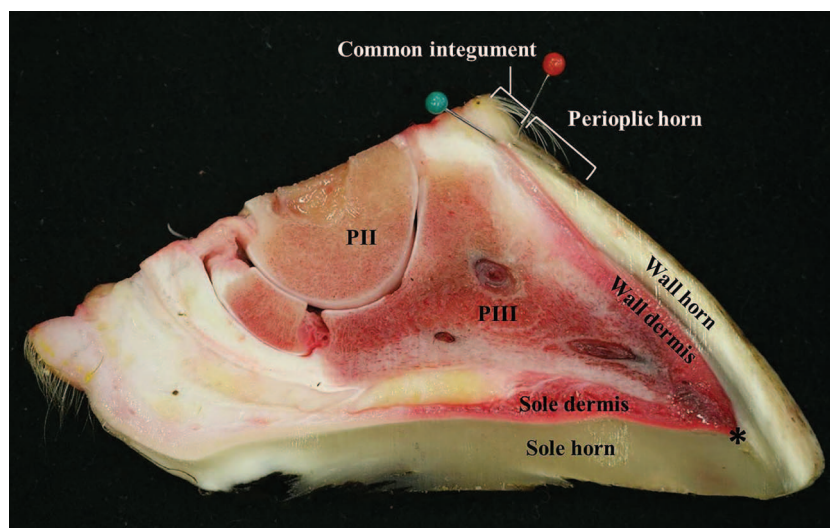


FIG 1: Sagittal prosection of a bovine claw demonstrating middle phalanx (PII), distal sesamoid bone, distal phalanx (PIII), the surrounding soft tissue, horn of the sole, wall and periople and the common integument. A green pin marks the proximal limit of the wall horn and an asterisk demonstrates the distal tip of the border between wall and dermis, which were the landmarks for CT measurement of dorsal wall length bordering the dermis. A red pin identifies the proximal limit of the periopic horn. The distal portion (~3 mm) of the common integument approaching the periopic horn is not haired

the hoof wall can lead to overtrimming. It is, therefore, important to appreciate the range of correct claw lengths that recommendations based on central tendencies summarise. Assuming that claw length is distributed normally, the consequences of applying mean values to cows selected at random from the population would be to overtrim around 50 per cent of claws. Blowey and Inman (2014) reported substantial variation in the dorsal wall length of pedal bones extracted *post mortem* from a range of culled cows and digit amputations; 40–85 mm for 49 claws with lesions and 50–76 mm for 65 claws without lesions. Assuming that correct hoof dorsal wall length is proportional to pedal bone dorsal wall length for a given sole thickness, this could lead to variation of up to 45 mm in the correct claw length that should be applied. Experienced foot trimmers vary claw length where the aim is to correct foot angles for optimal weightbearing (Manske and others 2002); the limitations of existing recommendations and variation with age have been highlighted (Nuss and Paulus 2006, Tsuka and others 2014).

Farm-level and cow-level data were lacking in previous studies that used abattoir material (Nuss and Paulus 2006, Tsuka and others 2014). The aim of this research was to describe variation in the length of the dorsal wall horn for cows from a known source, and hence, derive *minimum* claw lengths to update 'standard' foot trimming recommendations.

Materials and methods

Herd of origin

Holstein-Friesian cows in this study originated from the Scotland's Rural College Dairy Research Centre, Dumfries, UK. The centre had two units on the same site. Cows spent their initial lactations on the first unit, which had two management systems; a low-forage continuously housed group and a high-forage group with access to pasture from April to October. Management groups were further divided by cow genetic selection line producing a 2 × 2 factorial design (Pryce and others 1999, Chagunda and others 2009). Cows with feet deemed to be overgrown were trimmed by a professional hoof trimmer who attended biannually. Weekly locomotion scoring used the Manson and Leaver (1988) scale, and this underpinned lameness management on the unit, where lame cows received treatment as described by Randall and others (2015). In later lactations, some cows moved to the second unit before they were culled. Decisions on culling were made based on commercial or health and welfare considerations.

Hoof imaging

The hind feet of culled cows were collected *post mortem* at an abattoir, identified and transported on ice to University of Nottingham for storage at -20°C . The thawed feet underwent x-ray μCT scanning using a phoenix v|tome|x m industrial scanner (GE Sensing and Inspection Technologies, Wunstorf, Germany), at 125 kV and 320 μA . A 0.5 mm copper filter was used to reduce detector saturation, and samples were orientated to minimise scatter at the site of measurement. The distance between the x-ray source and the sample and the x-ray source and the detector was 450.29 mm and 818.69 mm, respectively, resulting in a magnification of $\times 1.82$ and a spatial resolution of 110 μm . Each scan acquired 2160 projection images over a 360° rotation of the sample using a detector exposure time of 333 ms, integrated over three averaged images, resulting in a total scan time of 48 minutes. Data were reconstructed for visualisation using datos|x software (GE Sensing), and internal claw dimensions were measured using VGStudio MAX V2.2 (Volume Graphics, Heidelberg, Germany).

Hoof measurements

A cross-sectional sagittal image through the dorsal ridge was used to determine the distance from the proximal limit of the wall horn to the tip of the dermis at the toe in each claw, the internal length of the dorsal wall (Fig 2a). A validation study was conducted to assess the relationship between the proximal limits of the wall horn identified on CT images and the overlying proximal limits of both the wall and periopic horn in *post mortem* specimens. Sagittal sections through the dorsal ridge of eight claws were prepared using a band saw, and distances between the proximal limit of both the wall and the overlying periopic horn were measured (Fig 1). The sites varied by no more than ± 2 mm, and the CT measurement of the limit of the wall horn was deemed to be a suitable indicator of the periopic horn landmark used during foot trimming.

The *minimum* recommended external dorsal wall length for each claw was estimated by adjusting the internal dorsal wall length measured by CT for adequate thickness of sole and wall when trimming the toe to a point, at an assumed claw angle of 50° (Fig 2b). A recommended *minimum* sole thickness of 5 mm (Laven and others 2012) was used. Validation work assessed the thickness of the wall at the distal tip of the dermis in a subset of 80 hind claws from 20 study cows; mean wall thickness was $8\text{ mm} \pm 0.9\text{ mm}$. A standard adjustment required for each claw

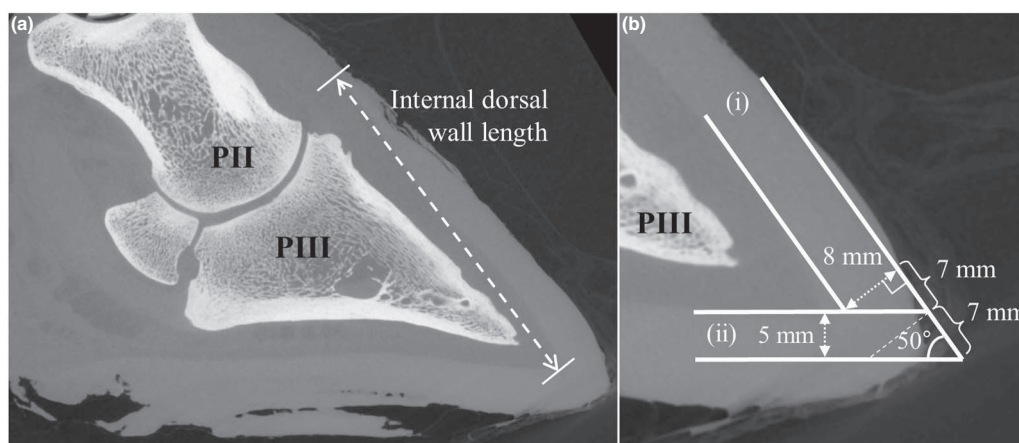


FIG 2: (a) Two-dimensional mid-sagittal CT image of a bovine claw demonstrating middle phalanx (PII), distal sesamoid bone, distal phalanx (PIII), surrounding soft tissue and the horn capsule. Internal dorsal wall length is marked, being the distance from the proximal limit of the wall horn to the tip of the dermis. (b) A magnification of the toe displaying PIII, the soft tissue and both the wall and the sole horn of the claw capsule. Parallel lines extrapolate from (i) the inner and outer aspect of the wall horn, which is assumed to be 8 mm thick, and (ii) the inner margin of the sole horn at the toe and 5 mm below this margin, representing the *minimum* safe sole thickness. The external lines demonstrate the shape of the toe if trimmed to a point. Deduction of adjustments was based on trigonometry using a toe angle of 50°. A dashed line marks a cut perpendicular to the direction of horn growth that would leave a step at the toe for a sole thickness of 5 mm

was calculated as 14 mm (7 mm+7 mm) using trigonometry (Fig 2b). Consequently, the *minimum* recommended cut length for trimming was derived by adding 14 mm to internal dorsal wall length measurements for each claw.

Statistical analysis

Cow-level data were collated from farm records. The outcome of interest was the dorsal wall length for the *i*-th hind claw (right lateral, right medial, left lateral or left medial) of the *j*-th cow. Potential cow-level explanatory variables were age at slaughter, parity at slaughter, management system on the first unit and genetic line. At the claw level, variables were constructed to indicate right or left, and lateral or medial. Evaluation used descriptive statistics and two-level linear regression models in the form of:

$$DWL_{ij} = \alpha + X_j\beta_1 + X_{ij}\beta_2 + u_j + e_{ij}$$

$$u_j \sim \text{Normal}(0, \sigma_u^2),$$

$$e_{ij} \sim \text{Normal}(0, \sigma_e^2),$$

where, DWL is dorsal wall length as measured using CT; X_j and X_{ij} are matrices of cow-level and claw-level exposure variables, respectively; β_1 and β_2 are vectors of coefficients; α is intercept value; u_j is random effect to account for residual variation between cows (assumed to be a normal distribution with mean=0 and variance σ_u^2) and e_{ij} is random effect to account for residual variation between claws (assumed to be a normal distribution with mean=0 and variance σ_e^2). Models were developed using the iterative generalised least squares algorithm in MLwiN and applying the Wald test to eliminate terms from a saturated model ($P \leq 0.05$; [Rasbash and others 2012](#)). Biologically plausible interactions were tested, and distributions of residuals were inspected to assess model fit. Variance components coefficients and the likelihood ratio test ($P \leq 0.05$) were evaluated to compare subsets of models ([Dohoo and others 2009](#)).

Results

The *minimum* external dorsal wall length required for trimming was determined for 219 hind claws (61 left lateral, 51 left medial, 54 right lateral and 53 right medial) collected from 68 cows culled between November 2013 and August 2014, and ranged from 66 to 93 mm (median (IQR)=83 mm (80–85 mm)), exceeding 90 mm for nine claws. Further description of measurement distributions is outlined in [Table 1](#).

Age at slaughter was the only explanatory variable retained in the final model ([Table 2](#)), and this explained 15 per cent of the variance in the null model. [Table 2](#) shows a linear association between change in age of one year and a 1 mm change in dorsal wall length (compared with a baseline mean dorsal wall length of 82 mm for a five-year-old cow). Model predictions are plotted against the observed data in [Fig 3](#); of the unexplained variance, 60 per cent were at the cow level, and 40 per cent were at the claw level within cow ([Table 2](#)). Alternative models were tested that included parity or age at slaughter as categorical terms in place of age as a continuous term; these explained 11 and 18 per cent of the null model variance, but the added complexity of including extra terms did not significantly improve model fit in either case. Distributions of residuals from the final model at the cow and claw levels were approximately normal.

Discussion

The authors measured the length of the dorsal wall in contact with the dermis, which must be avoided during foot trimming. A constant was added to leave a *minimum* sole thickness of 5 mm when trimming the toe to a point, at a toe angle of 50° and with a wall thickness of 8 mm. With this method, applying a dorsal wall length of 75 mm would have been too short for 95 per cent of claws overall. Trimming to 85 mm would have been adequate for animals less than four years of age (assumed to be in first and second lactation), but too short for 34 per cent of claws from cows aged at least four years ([Table 1](#)). This should not be surprising as minimum recommended dorsal wall length for the median claw from the 219 imaged was 83 mm. If the dorsal wall

TABLE 1: Descriptive statistics for *minimum* external dorsal hoof wall length (mm) based on 219 claws from the hind feet of 68 cows

	External dorsal wall length (proportions)				
	≤75 mm	≤80 mm	≤85 mm	≤90 mm	≤95 mm
All	0.05	0.25	0.73	0.96	1.00
<4 years	0.04	0.52	0.98	1.00	1.00
≥4 years	0.03	0.17	0.66	0.95	1.00
Claw					
Left lateral	0.03	0.20	0.70	0.93	1.00
Left medial	0.04	0.27	0.75	0.96	1.00
Right lateral	0.07	0.22	0.69	0.96	1.00
Right medial	0.04	0.30	0.77	0.98	1.00

TABLE 2: Final model for *minimum* external dorsal hoof wall length (mm)

Fixed part	Mean effect	se*
Intercept†	82	0.4
Age‡ (years)	1.0	0.2
Random part	Variance	se
Cow level	9.3	2.0
Claw level	6.5	0.7

*Variables are significant ($P \leq 0.05$) where the mean effect $\geq 1.96 \times \text{se}$ (Wald test)

†Five years old at slaughter

‡Change in *minimum* dorsal hoof wall length associated with a one-year change in age centered on five years old

were cut to 75 mm leaving a step (Fig 2b), 55 per cent of claws would have been cut too short.

The authors acknowledge that it is unlikely that experienced trimmers will use one cut length for all cows, but will vary it, for example, by size of cow or foot. However, where fixed lengths are to be applied at a population level, caution must be taken to minimise the proportion of claws for which that length is too short. Where fixed lengths are used to simplify protocols and facilitate the training of farm staff and other less experienced operators, the present study results suggest the *minimum* recommended length for trimming the external dorsal wall should be at least 90 mm for Holstein-Friesian cows, to reduce the risk of overtrimming. Applying measures of central tendency for recommendations does not allow for the variation demonstrated in claw length, and thresholds based on proportional measures are more appropriate. In addition to the pain elicited from cutting through sensitive tissue, overtrimming of the toe (even without drawing blood) can lead to a thin sole, disruption of load bearing, compression of the corium and, hence, sole haemorrhage and other claw horn lesions (Sanders and others 2009, Tsuka and others 2014). Once lameness has occurred, recurrent cases are more likely, leading to severely compromised lifetime productivity (Green and others 2014).

Definition of the proximal dorsal wall limit has been inconsistent between previous studies, and clarification was necessary for this work; the authors propose that the junction between hoof horn and common integument is used in the future as it appears to be the most consistently definable anatomical structure. The proximal limit of wall horn was identified on CT images. Use of this landmark increased measurement repeatability, and corresponded almost exactly with the proximal limit of

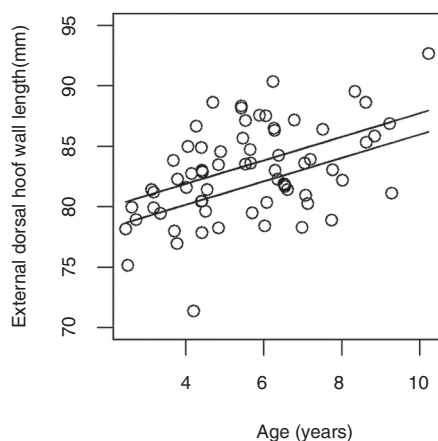


FIG 3: Relationship between age and the *minimum* external dorsal hoof wall length following trimming when a point is left at the toe for 219 claws from 68 cows. Solid lines are the bounds of the 95 per cent CI for the fitted mean, points are observed data as cow-level means

perioplic horn, which has been described as the proximal landmark for dorsal wall length in other work (Manske and others 2002). A variety of alternative landmarks for measurements have been described, and readers using these landmarks will need to make appropriate adjustments to the present study recommendations to obtain the appropriate dorsal wall length.

In agreement with increasing recommended claw length, Tsuka and others (2014) suggested 79 mm was more appropriate than 75 mm, and Nuss and Paulus (2006) reported a cut length of 80 mm left 29 per cent of claws with inadequate sole depth. The current study reports longer lengths may be required, but the authors assumed that the toe would be trimmed to a point. It is unknown if leaving a step or a point is important, indicating an area where further research is needed.

Cow age was the only significant variable associated with dorsal wall length in this study; an observation made before for claws from German Simmental cows (Nuss and Paulus 2006). Kehler and Sohr (2000) also concluded that 5–8 mm should be added to the existing recommendation of 75 mm in older cattle to account for size difference with age. A linear association with an effect size of 1 mm per year of age was demonstrated in this study. No difference in measurements was observed between lateral and medial claws. A limitation with regard to the management and production history of cows in the current study was time spent on a second unit before culling. This may have contributed to the failure to identify further associations, and as a result 85 per cent of the observed variation in external dorsal hoof wall length remained unexplained. Alternatively, the unexplained variation could be attributable to unrecorded variables, such as measures of cow stature and bodyweight. At present, any variation in claw length applied by foot trimmers must be based solely on their experience and judgement. For practical use, further studies should consider associations with claw length and cow-side measures of stature and conformation that could be assessed by the operator immediately before trimming the hoof dorsal wall. Predictors of dorsal wall length would be of more use at the cow level than at the claw level as this is where most variation resided (Table 2).

Data on claw lesions at slaughter were not collected in this study. As lameness occurs most frequently in older, higher yielding cows (Green and others 2002, Archer and others 2010b), age would likely be correlated with the presence of claw horn lesions and dorsal wall length. Any curvature of the external hoof wall was not accounted for, and external dorsal wall length was assumed to be a straight line (Fig 2). The authors consider this an appropriate simplification for practical application.

X-ray μ CT was useful in this study, enabling non-destructive high resolution assessment of hoof anatomy. A limitation was the difficulty in defining the proximal limit of the dorsal wall due to the homogenous radiopacity of the surrounding soft tissues, but this was addressed by comparison with dissected claws. Further, the authors assumed a minimum sole thickness of 5 mm from previous recommendations (Laven and others 2012); operators wishing to leave a greater thickness of sole will need to increase the present study recommendations to allow for an increase in sole depth following trimming.

Conclusion

Although this study was carried out on cows from a single farm, in the absence of larger studies to date, the authors propose that the *minimum* recommended claw length for any Holstein-Friesian adult dairy cow should be increased to at least 90 mm, measured from the proximal limit of wall horn, when trimming the toe to a point. Small reductions can be made for younger animals, for example, 85 mm would be appropriate for the majority of first-lactation and second-lactation cows. If a step is left at the toe, the minimum recommended length should be 85 mm. While the authors acknowledge that many competent hoof trimmers will vary dorsal wall length within safe limits, the large unexplained variation within the small population presented in the present work suggests it is imperative that 'standard' measures of dorsal

wall length used by less experienced operators be increased in future texts and training material. Finally, authors should be clear about where the dorsal wall is measured from and whether they advocate the toe being trimmed to a point or left with a step, detailing the size of that step. These measures will reduce the risk of overtrimming by the less experienced operator and allow better comparisons between recommendations from different sources in the future.

Acknowledgements

The authors thank staff at the Hounsfield Facility, University of Nottingham for advice on CT scanning, and staff at the SRUC Dairy Research Centre, Dave Roberts and Maggie March, for their cooperation and help accessing data.

Funding The work reported here was funded in-part by the Agriculture and Horticulture Development Board (AHDB), Dairy Division, a levy board, not for profit organisation working on behalf of British Dairy Farmers (grant number RC3812). The Hounsfield Facility received funding from ERC, BBSRC and The Wolfson Foundation, and SRUC received financial support from the Scottish Government.

Open Access This is an Open Access article distributed in accordance with the Creative Commons Attribution Non Commercial (CC BY-NC 4.0) license, which permits others to distribute, remix, adapt, build upon this work non-commercially, and license their derivative works on different terms, provided the original work is properly cited and the use is non-commercial. See: <http://creativecommons.org/licenses/by-nc/4.0/>

References

- ARCHER, S. C., BELL, N. J. & HUXLEY, J. H. (2010a) Lameness in UK dairy cows: a review of the current status. *In Practice* **32**, 492–504
- ARCHER, S. C., GREEN, M. J. & HUXLEY, J. N. (2010b) Association between milk yield and serial locomotion score assessments in UK dairy cows. *Journal of Dairy Science* **93**, 4045–4053
- BICALHO, R. C. & OIKONOMOU, G. (2013) Control and prevention of lameness associated with claw lesions in dairy cows. *Livestock Science* **156**, 96–105
- BLOWEY, R. (2004) Lameness in the foot. In *Bovine Medicine*. 2nd edn. Ed A. H. ANDREWS. Oxford, UK: Blackwell Science Ltd. pp 409–434
- BLOWEY, R. (2008) Foot structure, function and inflammation. In *Cattle Lameness and Hoofcare*. 2nd edn. Ed R. BLOWEY. Ipswich, UK: Old Pond Publishing Ltd. pp 12–33
- BLOWEY, R. & INMAN, B. (2014) The relevance of changes in pedal bone and hoof dimensions in relation to foot trimming protocols. *28th World Buiatrics Congress*. Cairns, Australia. pp 25–26
- CHAGUNDA, M. G. G., RÖMER, D. A. M. & ROBERTS, D. J. (2009) Effect of genotype and feeding regime on enteric methane, non-milk nitrogen and performance of dairy cows during the winter feeding period. *Livestock Science* **122**, 323–332
- DOHOO, I., MARTIN, W. & STRYHM, H. (2009) *Veterinary Epidemiological Research*. 2nd edn. Prince Edward Island, Canada: VER Inc
- GREEN, L. E., HEDGES, V. J., SCHUKKEN, Y. H., BLOWEY, R. W. & PACKINGTON, A. J. (2002) The impact of clinical lameness on the milk yield of dairy cows. *Journal of Dairy Science* **85**, 2250–2256
- GREEN, L. E., HUXLEY, J. N., BANKS, C. & GREEN, M. J. (2014) Temporal associations between low body condition, lameness and milk yield in a UK dairy herd. *Preventive Veterinary Medicine* **113**, 63–71
- GREENOUGH, P. R. (2007) *Bovine Laminitis and Lameness: A Hands on Approach*. Philadelphia: Saunders, Elsevier Ltd
- HUXLEY, J. N. (2013) Impact of lameness and claw lesions in cows on health and production. *Livestock Science* **156**, 64–70
- KEHLER, W. & SOHRT, J. T. (2000) Standard measurements of the normal hind claw of Holstein Friesian cows: the relation between the internal anatomical structure and the horn capsule. *11th International Symposium on Disorders of the Ruminant Digit and 3rd International Conference on Bovine Lameness*. Parma, Italy
- LAVEN, L. J., MARGERISON, J. K. & LAVEN, R. A. (2012) Validation of a portable ultrasound machine for estimating sole thickness in dairy cattle in New Zealand. *New Zealand Veterinary Journal* **60**, 123–128
- MANSKE, T., HULTGREN, J. & BERGSTEN, C. (2002) The effect of claw trimming on the hoof health of Swedish dairy cattle. *Preventive Veterinary Medicine* **54**, 113–129
- MANSON, F. J. & LEAVER, J. D. (1988) The influence of concentrate amount on locomotion and clinical lameness in dairy cattle. *Animal Production* **47**, 185–190
- MULLING, C. & BUDRAS, K. D. (2003) Pelvic limb. In *Bovine Anatomy*. Ed K. D. BUDRAS. Hans-Böckler-Allee 7, 30173. Hannover, Germany: Schlutersche GmbH & Co. KG, Verlag and Druckerei. pp 24–27
- NUSS, K. & PAULUS, N. (2006) Measurements of claw dimensions in cows before and after functional trimming: A post-mortem study. *Veterinary Journal* **172**, 284–292
- PRYCE, J. E., NIELSEN, B. L., VEERKAMP, R. F. & SIMM, G. (1999) Genotype and feeding system effects and interactions for health and fertility traits in dairy cattle. *Livestock Production Science* **57**, 193–201
- RANDALL, L. V., GREEN, M. J., CHAGUNDA, M. G. G., MASON, C., ARCHER, S. C., GREEN, L. E. & HUXLEY, J. N. (2015) Low body condition predisposes cattle to lameness: An 8-year study of one dairy herd. *Journal of Dairy Science* **98**, 3766–3777
- RASBASH, J., STEELE, E., BROWNE, W. J. & GOLDSTEIN, H. (2012) *A User's Guide to MLwiN, v2.26*. Centre for Multilevel Modelling, University of Bristol
- SANDERS, A. H., SHEARER, J. K. & DE VRIES, A. (2009) Seasonal incidence of lameness and risk factors associated with thin soles, white line disease, ulcers, and sole punctures in dairy cattle. *Journal of Dairy Science* **92**, 3165–3174
- TOUSSAINT-RAVEN, E. (1985) *Cattle Footcare and Claw Trimming*. Ipswich, UK: Farming Press Ltd
- TSUKA, T., MURAHATA, Y., AZUMA, K., OSAKI, T., ITO, N., OKAMOTO, Y. & IMAGAWA, T. (2014) Quantitative evaluation of the relationship between dorsal wall length, sole thickness, and rotation of the distal phalanx in the bovine claw using computed tomography. *Journal of Dairy Science* **97**, 6271–6285



CrossMark

Claw length recommendations for dairy cow foot trimming

S. C. Archer, R. Newsome, H. Dibble, C. J. Sturrock, M. G. G. Chagunda, C. S. Mason and J. N. Huxley

Veterinary Record published online July 28, 2015

Updated information and services can be found at:

<http://veterinaryrecord.bmj.com/content/early/2015/07/28/vr.103197>

These include:

References

This article cites 15 articles, 1 of which you can access for free at: <http://veterinaryrecord.bmj.com/content/early/2015/07/28/vr.103197#BIBL>

Open Access

This is an Open Access article distributed in accordance with the Creative Commons Attribution Non Commercial (CC BY-NC 4.0) license, which permits others to distribute, remix, adapt, build upon this work non-commercially, and license their derivative works on different terms, provided the original work is properly cited and the use is non-commercial. See: <http://creativecommons.org/licenses/by-nc/4.0/>

Email alerting service

Receive free email alerts when new articles cite this article. Sign up in the box at the top right corner of the online article.

Topic Collections

Articles on similar topics can be found in the following collections

[Open access](#) (76)

Notes

To request permissions go to:

<http://group.bmj.com/group/rights-licensing/permissions>

To order reprints go to:

<http://journals.bmj.com/cgi/reprintform>

To subscribe to BMJ go to:

<http://group.bmj.com/subscribe/>